

A Combined TMS/fMRI Study of Intensity-Dependent TMS Over Motor Cortex

Daryl E. Bohning, Ananda Shastri, Kathleen A. McConnell, Ziad Nahas, Jeffrey P. Lorberbaum, Donna R. Roberts, Charlotte Teneback, Diana J. Vincent, and Mark S. George

Background: *Transcranial magnetic stimulation (TMS) allows noninvasive stimulation of neurons using time-varying magnetic fields. Researchers have begun combining TMS with functional imaging to simultaneously stimulate and image brain activity. Recently, the feasibility of interleaving TMS with functional magnetic resonance imaging (fMRI) was demonstrated. This study tests this new method to determine if TMS at different intensities shows different local and remote activation.*

Methods: *Within a 1.5 Tesla (T) MRI scanner, seven adults were stimulated with a figure-eight TMS coil over the left motor cortex for thumb, while continuously acquiring blood oxygen level dependent (BOLD) echoplanar images. TMS was applied at 1 Hz in 18-second long trains delivered alternately at 110% and 80% of motor threshold separated by rest periods.*

Results: *Though the TMS coil caused some artifacts and reduced the signal to noise ratio (SNR), higher intensity TMS caused greater activation than lower, both locally and remotely. The magnitude ($\approx 3\%$ increase) and temporal onset (2 to 5 sec) of TMS induced blood flow changes appear similar to those induced using other motor and cognitive tasks.*

Conclusions: *Though work remains in refining this potentially powerful method, combined TMS/fMRI is both technically feasible and produces measurable dose-dependent changes in brain activity.* Biol Psychiatry 1999;45:385–394 © 1999 Society of Biological Psychiatry

Key Words: Transcranial magnetic stimulation, motor cortex, fMRI, blood flow, imaging

Introduction

Transcranial magnetic stimulation (TMS) is a new neuroscience tool that allows noninvasive stimulation of neurons (George et al 1996). It has been used as a brain mapping tool (Grafman et al 1994) and has demonstrated therapeutic potential for treating depression (George and Wassermann 1994; George et al 1995; Pascual-Leone et al 1996; Figiel et al 1998). Recently, researchers have begun combining TMS with functional imaging to stimulate and simultaneously image brain activity (George et al 1997a). Previous imaging work has been done with fluorodeoxyglucose (FDG) (George et al 1995; Kimbrell et al 1997) and oxygen (O15) positron emission tomography (PET) (Paus et al 1997; Paus et al 1998), perfusion single photon emission computed tomography (SPECT) (Stallings et al 1997; Nahas et al 1998), and electroencephalography (EEG) (Ilmoniemi et al 1997). Our group recently demonstrated the feasibility of interleaving TMS with functional magnetic resonance imaging (fMRI), allowing for imaging TMS effects with excellent temporal and spatial resolution (Bohning et al 1997; Bohning et al 1998). Although we have previously shown that interleaved TMS and fMRI is feasible, it is unclear whether this combination is useful to understand and image brain function for neuroscience research. We therefore carried out the following study examining the effects of different intensities of TMS over the same motor cortex region in seven healthy adult subjects.

We hypothesized that if combined TMS/fMRI was a viable combination, TMS at different intensities above and below the motor threshold would produce slightly different local and remote changes in blood flow observable by fMRI, and because the intensities were close, the auditory and somatosensory effects would be similar. We chose to stimulate over the motor cortex area for the thumb because the observed thumb movement provided independent verification of functional location across and within subjects. Our choice of motor cortex also provided the opportunity to compare the effects of stimulation above and below motor threshold. Stimulation at the abductor pollicis brevis (APB) site above motor threshold, by definition, produces

From the Functional Neuroimaging Research Division, Departments of Radiology (DEB, AS, KAM, DRR, DJV, MSG), Psychiatry (ZN, JPL, CT, MSG), and Neurology (MSG), Medical University of South Carolina, Charleston; and the Ralph H. Johnson Veterans Hospital (MSG), Charleston, South Carolina.

Address reprint requests to Daryl E. Bohning, PhD, Radiology Department, Medical University of South Carolina, 171 Ashley Avenue, Charleston, South Carolina 29425.

Received September 3, 1998; revised November 16, 1998; accepted November 19, 1998.

movement in the contralateral thumb and is thus known to activate the corticospinal output system.

Methods and Materials

General Experimental Design

Subjects were seven healthy adults (mean age 34.3 years, SD 10.1; three women; one left-handed person) who signed an appropriate consent form approved by the MUSC Institutional Review Board. Interleaved TMS/fMRI acquisitions were performed in a Picker EDGE 1.5 T MR scanner with actively shielded magnet and high-performance gradients (27 mT/m, 72 T/m/sec) using a typical gradient echo, echoplanar (EPI) fMRI sequence (tip angle = 90°, TE = 40.0 ms, TR = infinite, FOV = 27.0 cm, twelve 5 mm thick slices, 1.5 mm gap, with frequency selective fat suppression). TMS was done using a Dantec MagPro with a special nonferromagnetic TMS coil of figure-8 design with an 8 m cable (Dantec Medical A/S, Skovlunde, Denmark). The stimulator console was placed about 4 m from the MR magnet just outside the rear door of the scanning room. The open doorway was radiofrequency (RF) shielded with a panel consisting of a nonferromagnetic frame covered with aluminum screen and edged with metal spring contacts for an RF tight fit in the door frame. The 8 meter TMS cable, shielded with an aluminum mesh sheath, was passed into the scanner room through a hole in the bottom right corner of the screen. The bore of the MR magnet was also RF shielded using a cone of aluminum screen which enclosed the subjects' legs, fitting a few inches into the bore of the magnet and held in place with a plastic hoop to make the RF seal.

The relative timing of EPI acquisitions and TMS stimulation was controlled using a PowerMac 7100/80AV (Apple Computer, Inc., Cupertino, CA) with general purpose I/O (Input/Output) board (NB-MIO-16XH) and LabView software package (National Instruments Corp., Austin, TX). The EPI acquisitions were performed normally in a free running steady-state mode, while the PowerMac counted the RF synchronization pulses generated by the scanner for each acquisition. At the appropriate counts, the PowerMac generated a TTL (5V Transistor Transistor Logic) pulse through the I/O board to trigger the Dantec MagPro via its external triggering feature (Shastri et al 1998). The entire TMS/fMRI sequence (864 sec, 14.4 min), consisted of eight cycles. Each cycles, illustrated below (Figure 1), consisted of six 18-sec subcycles, four rest and two task. During each subcycle, the scanner acquired six sets of 12 coronal images centered around the motor cortex, or one full set of brain images every 3 sec. During the task subcycles the TMS was triggered 100 ms after every fourth image acquisition to produce a TMS stimulation rate of 1 Hz.

TMS Coil Placement

The TMS coil was rigidly mounted in the MR head coil with vitamin E capsules placed at the ends of the TMS coil, behind it, and at its center, to help locate it in the structural images. Subjects wore earplugs; vision was unconstrained. With the head coil on the gantry outside of the scanner bore, subjects would

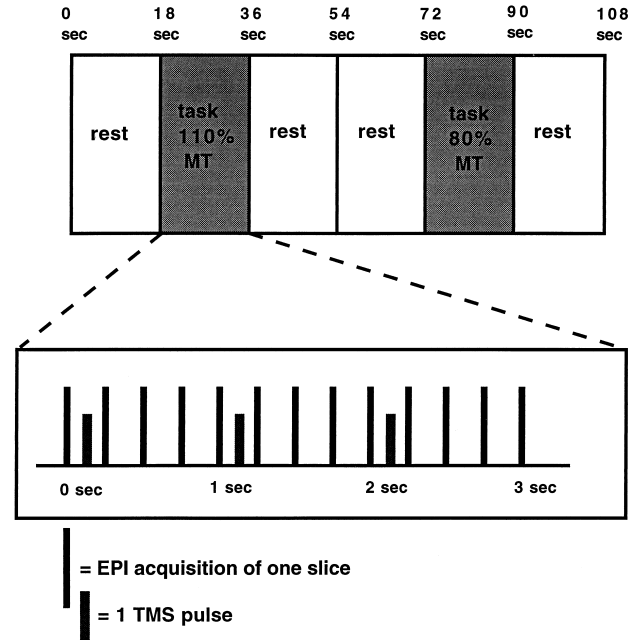


Figure 1. Relative timing of the interleaved TMS stimulus and fMRI scanning used in the study. The entire TMS/fMRI sequence consists of eight cycles. One cycle, illustrated above, consists of six 18-sec subcycles, four rest and two task. During each subcycles, the scanner acquires six sets of 12 coronal images over the motorcortex, or one full set every three sec. During the task subcycles, the TMS fires 100 ms after every fourth image acquisition.

insert their head into the head coil and adjust their position while the TMS coil was intermittently pulsed with high intensity (90% machine output when MT was unknown, lower in subjects who knew their approximate MT from previous studies with the Dantec). Subjects adjusted their head until pulsing the coil caused visible movement of the contralateral (right) hand abductor pollicis brevis (thumb). Formal EMG determination of the MT was not possible due to the high magnetic field, although with this machine (Dantec) we have found a close concordance between EMG and visually determined MT (Pridmore et al 1998). The head was then stabilized with foam padded inflatable restraints. Motor threshold (MT) for right thumb was determined by gradually decreasing stimulation intensity until movement (slight twitch) was no longer observed. Motor threshold (MT) for that individual was thus the intensity setting on the Dantec (in 5% increments) that produced visible twitch in the thumb at least 50% of the time over 10 pulses. TMS stimulation level was then set at 110% of MT ("high") or 80% MT ("low"). The subject was then moved into scanning position in the scanner bore and the TMS machine pulsed again to ensure that no movement had occurred. After scanner tuning and acquisition of T1-weighted reference images and phase maps (Bohning et al 1997), and before the TMS/fMRI BOLD acquisition was started, the TMS coil to head position was rechecked with one or more individual manual TMS pulses to determine that contralateral thumb move-

ment still occurred with stimulation at and above MT and did not occur with stimulation below MT.

Image Data Analysis

All images were translated into ANALYZE (CNSoftware, Ltd., West Sussex, UK) format and moved to Sun SPARCstations for further analysis.

MOVEMENT DETERMINATION AND CORRECTION. An initial analysis of movement across the 14.4 min run was performed using MEDx (Sensor Systems, Inc., Sterling, VA). All studies met our requirement of movement less than 3 mm and were thus included for final analysis. BOLD images were coregistered to a common mean image using the software program Automated Image Registration (AIR) (Woods et al 1992).

INITIAL COMPARISON. Paired *t* tests were then performed between images during TMS and those just before TMS to generate *t*-maps of significant pixels ($p < .001$) that vary across the three pairs of conditions, high stimulation (110%MT) minus rest, low stimulation (80%MT) minus rest, and high minus low (Functional Image Data Analysis Platform (FIDAP) Haxby and Maisog, NIMH). The initial two scans from each epoch were not used, to allow for hemodynamic lag. This generated a *t*-map of all pixels that significantly vary across two conditions.

CLUSTER ANALYSIS TO ACCOUNT FOR MULTIPLE COMPARISONS. Next, we quantitatively corrected for multiple comparisons by performing a particle or cluster analysis that takes all pixels that meet a certain statistical threshold (in this case $p < .001$) and then subjects these pixels to an additional analysis where pixels are assigned a new statistical weighting based on the activity of neighboring pixels (Forman et al 1995). This particle analysis operates under the assumption that large contiguous areas of activation are less likely artifact than single pixels. Using FIDAP, we converted *t*-maps to *Z*-maps ($p < 0.001$) using the appropriate number of degrees of freedom. Note that a *Z* score of 3.09 corresponds to a *p* value of .001. After creating a *Z*-map mask with statistical threshold .02, we used FIDAP to perform the particle analysis on the "masked" *Z*-maps, thresholded at 3.09. In the particle analysis, each group of connected activated pixels ($p > .001$) was considered to belong to a cluster, and assigned a statistical weight based on the number and *Z* scores of the pixels in it. We set our threshold for clusters at $p < .05$. Using ANALYZE, these cluster maps ($p < .05$) were merged onto structural MRI scans obtained in the same slice. The merged images were then inspected for regions which consistently showed significant activation across subjects.

Results

Safety, Tolerability, and Side-Effects

None of the volunteers reported any movement of the TMS coil that might indicate its interaction with either the MR scanner's main magnetic field or switched gradients.

Importantly, supra-MT ("high") stimulation still produced visible thumb movement at the end of the 14.4-min run, implying no significant movement of the TMS coil during the image acquisition. Subjects did report that the TMS coil was louder when they were inside the MR scanner due to the acoustics of the bore, and, possibly, additional stresses inside the TMS coil, but there was no apparent affect on MT. The TMS noise, in addition to being louder than the EPI noise, was also intermittent, compared to the rhythmic noise of EPI imaging. However, all subjects tolerated the scanning procedure without problems or side effects. Two subjects underwent formal testing of vigilance and motor speed (Continuous Performance Task, Rosvol et al 1956) before and after the TMS/fMRI sessions and no changes were noted. None of the subjects developed headaches.

Scan Quality: Movement, Signal to Noise Ratio (SNR) and Artifact

For all data sets, movement across the 14.4-min long study was less than 3 mm in all three axes. The mean \pm standard deviation (SD) of the signal-to-noise ratio (SNR) was 78.7 ± 41.6 (Noise was measured in a circle outside of the brain in the upper right quadrant of the image, the signal was taken in a similar circle over the right brain, mainly centered over white matter with care taken to avoid the ventricles [$SNR = (\text{mean}_{\text{signal}} - \text{mean}_{\text{noise}})/SD_{\text{noise}}$]).

Coronal MRI images of one subject directly below the TMS coil are shown in Figure 2. Areas of significant activation are superimposed in color, the degree of activation increasing from yellow to orange to red, with the TMS coil drawn on the figure.

STUDIES OF POTENTIAL ARTIFACT. We previously performed imaging studies on phantoms where we stimulated with TMS and acquired data as in these human studies. Using a similar rigorous statistical analysis, we found no voxels that falsely activate (Shastri et al 1999). Thus, we are confident that this technique does not produce false-positive areas of activation. However, we are less confident as to whether or not the combined TMS/fMRI technique used here might obscure activation by producing artifact that interferes with the ability to acquire functional imaging data in some brain regions. In some studies, we noted areas of decreased signal, which we think is from a switch in the TMS coil handle. This was never seen on the slice immediately below the center of the coil; rather, it was several slices anterior. Though less obvious than the "switch" artifact, some susceptibility-induced reduction in signal can be seen directly under the TMS coil. To test whether there may be loss of signal in specific brain regions that is caused by the TMS coil in the

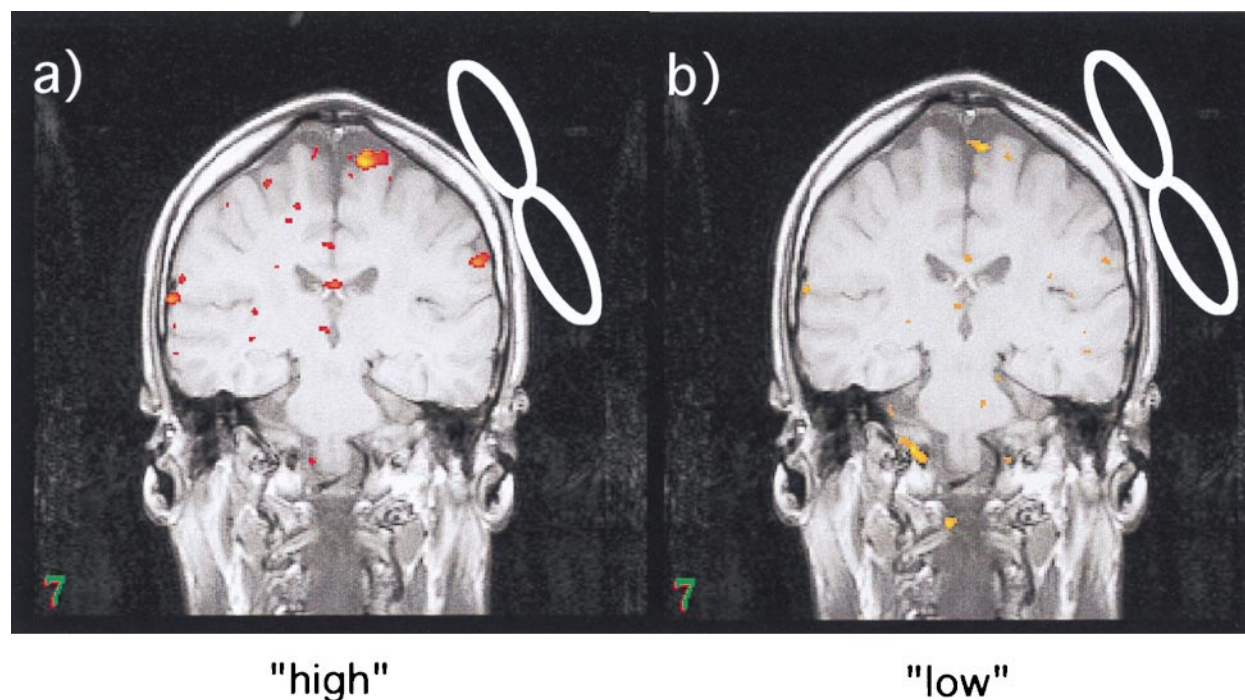


Figure 2. Coronal MRI images of one subject directly below the TMS coil. (A) 110% MT (high) and (B) 80% MT (low). Areas of significant ($p < .001$) activation are superimposed in color, activity increasing from yellow to orange to red, and the position of the coil has been indicated. Note the increased number of significant pixels in this subject during the high intensity stimulation task (HMR), and the relative absence of activity directly under the coil.

scanner, we used the scanner's software to draw circular regions over cortex and sample image intensity on the raw BOLD weighted images. These were placed directly under the coil, on flanking sites in surrounding cortex, and over white matter regions deeper (1 cm) into the brain. A similar set of regions at mirror sites in the opposite cortex were sampled for comparison. Signal intensity in these regions was normalized to background activity. Though the SNR in the three regions immediately below the coil (64.3 ± 34.0) was lower than in those in the opposite hemisphere (72.3 ± 35.4), the difference was not statistically significant (Student's t test, $t = 1.667$; $p = .0733$). This is consistent with the $26.2 \pm .5\%$ signal loss observed in phantom studies due to the susceptibility artifact from the presence of the TMS coil. A structural image of the phantom with the susceptibility-induced phase shift contours determined by MR phase maps (Bohning et al 1997) superimposed is shown in Figure 3A. Figure 3B and Figure 3C, respectively, show the relative magnetic field shift and signal intensity as functions of distance from the coil along the line drawn on the image of the phantom in Figure 3A. In the spherical phantom, this field shift artifact (Figure 3B), phase shift relative to baseline, peaked at .35 parts per million (ppm) under the center of the coil 1 cm deep (about the depth of the cerebral

cortex), falling to approximately .11 ppm at 3 cm (corresponding to 2 cm into the brain). The signal intensity in these structural images is relatively insensitive to the field shift compared with the fMRI EPI images, with Figure 3C showing only the fall of signal at the edges of the field of view usually seen with this MR scanner.

Regional Brain Activation

Summed across all brain locations, the total number of significant pixels (after cluster analysis) by comparison, pooled across all subjects, is shown in Figure 4. There was significantly more brain activation during supra-MT stimulation compared to rest (HMR) than during sub-MT stimulation compared to rest (LMR) (HMR mean 224 ± 276 ; LMR mean 49 ± 76 ; Student's paired t test, $t = 2.12$; $df = 6$; $p = .04$).

Analyzed by region and intensity, the most activation occurred during supra-MT stimulation in the ipsilateral motor cortex. The number of significant pixels in each cluster and the cluster's location on the images is generated by FIDAP. For this analysis, the significant clusters were printed as text and then, displaying the structural/functional merged scans on a workstation console, the clusters were defined by region by a trained observer

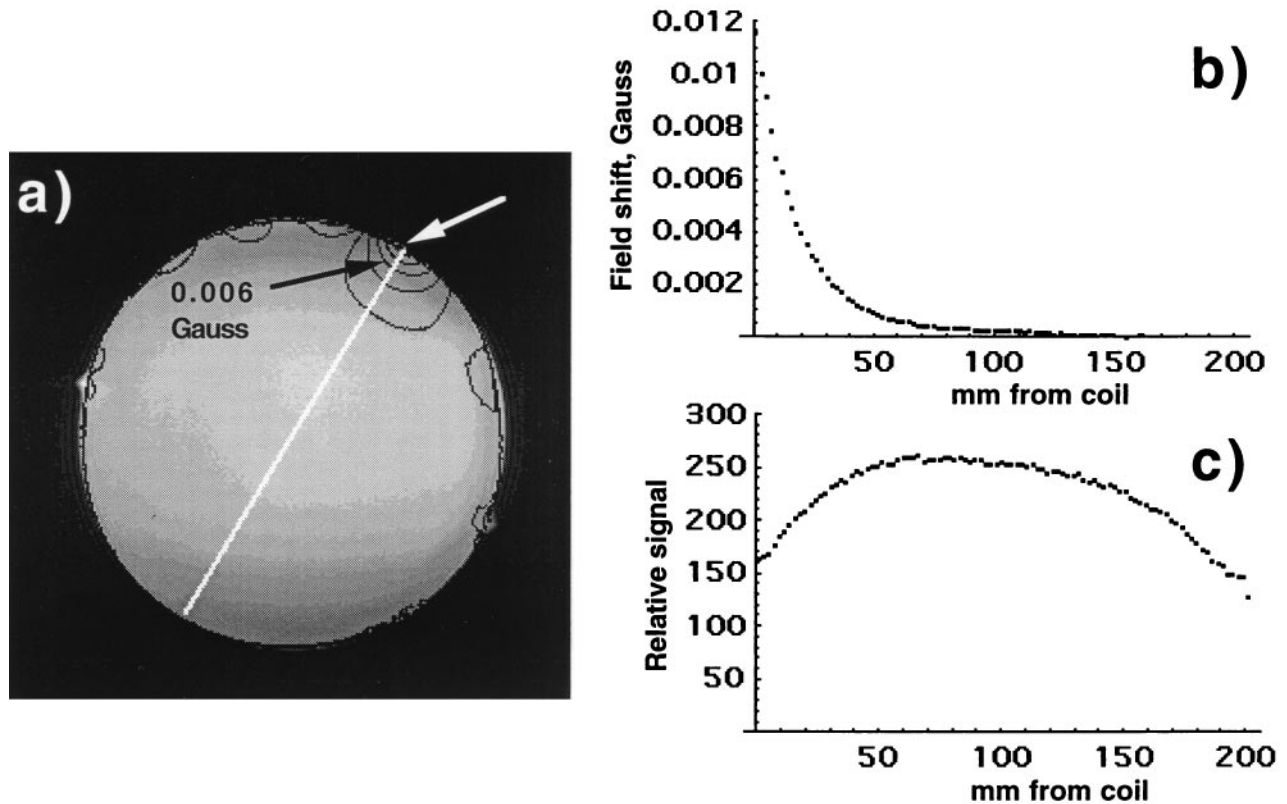


Figure 3. Susceptibility-induced phase shift due to presence of TMS coil. (A) Phase map of field shift superimposed on MRI image of spherical phantom. (B) Plot of field shift versus distance from coil along line (white arrow) and (C) plot of signal intensity versus distance from coil along line (white arrow). Black arrow indicates 0.006 Gauss contour.

(KAM) and confirmed by another reader (MSG). The different regions activated across all subjects, divided by comparison (HMR and LMR), are shown in Figure 5.

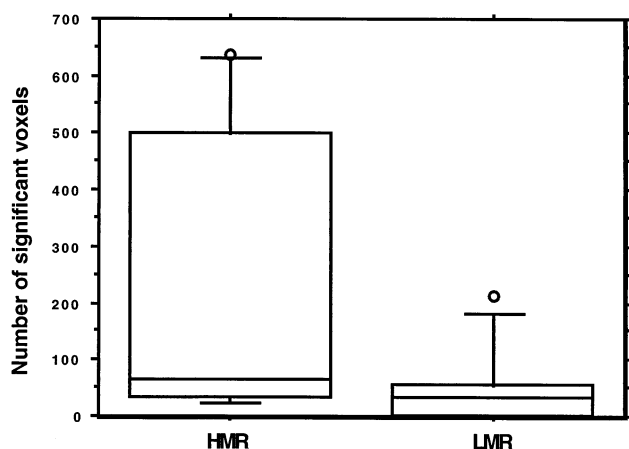


Figure 4. Box plot showing the total number of voxels that meet the stringent double screen criteria separated by comparison of high intensity minus rest (HMR), low intensity minus rest (LMR), and high minus low intensity. Note that TMS at an intensity above motor threshold (HMR) produced more activation both locally and remotely than did lower intensity TMS (LMR) (Student's *t* test, 6 df, $t = 2.12$, $p < .05$).

To gauge the strength of observed BOLD activity in relation to noise and to clarify the nature of possible TMS-induced artifact, we examined the time-activity behavior of clusters from a number of areas (Table 1). Some areas were identified by particle analysis as having significant activation, and other areas were chosen strictly by location, either near, or remote from the site of TMS stimulation. For each area, the cycle-averaged time-activity curve was plotted and an estimate was obtained of the level of activity in the supra-TMS subcycle relative to the preceding rest subcycle. This value and the mean Z score (in parentheses) for the associated cluster for each area, by subject, appear in Table 1.

The clusters were chosen as follows. In subjects where a cluster of activity was found on the HMR contrast in ipsilateral motor cortex, this was used for the time-activity curve. In subjects where no pixels met this rigorous threshold on the HMR, we returned to the original *t*-map and thresholded the images to find the clusters with most significant activation in that area, even if those regions did not make the final statistical screen. Figure 6 summarizes the time-activity data pooled across all subjects. Figure 6A through Figure 6E show the composites across all subjects of the cycle-averaged changes in BOLD activity

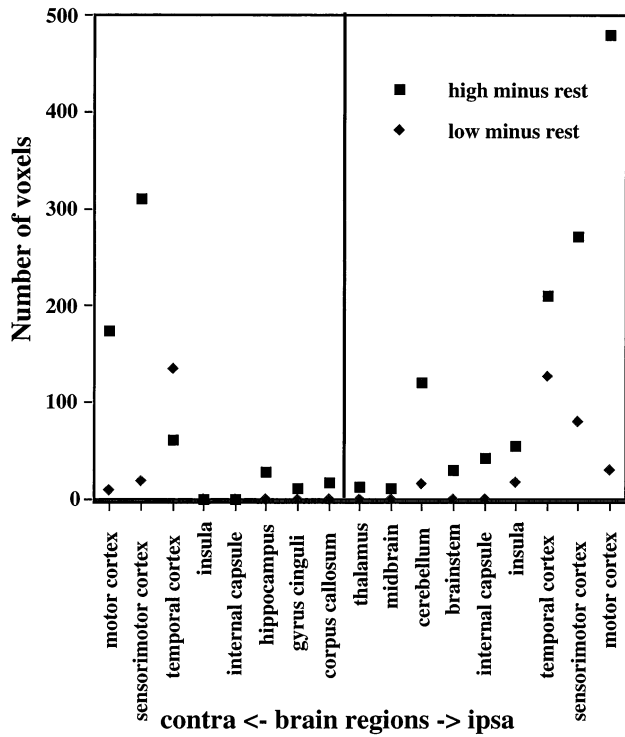


Figure 5. Total number of significant voxels in discrete brain regions summed across all seven subjects, high intensity minus rest (■) and low intensity minus rest (◆). High intensity stimulation significantly increased activity both locally and remotely (trans-synaptically), demonstrating the potential of this method for selectively stimulating and imaging brain circuits, although much work and refinement of technique is needed.

versus cycle time in the five areas (Table 1) referenced to the structural image in Figure 6F to show the approximate area in which the associated cluster was located.

Figure 6A (noise) is the time-activity curve for an area remote from the TMS coil without activity and gives a measure of the level of noise in the curves. To gauge nonspecific activity under the TMS coil (Figure 6B, coil), the time-activity curve was plotted for a cluster of pixels about 1 cm deep in cerebral cortex under the coil as determined from the vitamin-E capsule fiducials, irrespec-

tive of any activation. Figure 6D (motor) is for areas that could be reasonably assigned to the motor cortex. Figure 6E (auditory) is for areas likely to be auditory cortex, which was chosen because of its prominence in most of the subjects. Figure 6C (vein) is from an area that is probably vein, and, like the auditory area, was present in most subjects. High intensity TMS produced a slightly greater magnitude increase in percent change BOLD effect in all three response areas, motor, auditory, and vein. Time-intensity curves were produced with Mathematica (Wolfram Research, Inc., Champaign, IL).

Discussion

This study tested whether the new method of combining TMS with echoplanar BOLD fMRI was able to show subtle differences in TMS-induced behavior. We thus chose to study an easily demonstrable behavior (thumb movement) and simultaneously stimulated and imaged while alternating between the two slightly different TMS intensities. Our results are consistent with the notion that high intensity stimulation is associated with significantly increased activity both locally and remotely (trans-synaptically) compared to both the rest condition and to TMS at lower intensity (in some analyses such as the time-activity curves). The TMS effects we observed were of a magnitude (3 to 4% increase in BOLD signal) and time domain (lag of several seconds) similar to other neuropsychological tasks. These preliminary data thus demonstrate the potential of this method for selectively stimulating and imaging brain circuits, although the technique clearly needs development and refinement. Notable limitations of the technique merit discussion.

There is no evidence, either in the phantom data or in the human studies, of spurious nonspecific activation due to the coils' presence or movement in physical contact with the head when the coil is pulsed. Furthermore, signal time course curves taken from areas under the coil do not show the response pattern seen in activated clusters.

There is reduced signal under the coil compared to a

Table 1. Percent BOLD-fMRI response and mean Z score (in parentheses) for "high" intensity TMS relative to rest for activated "clusters" in selected areas by subject

Subject Number	Noise	Coil	Motor	Auditory	Medial Vein	Fiducial Slice	SNR
1	-0.3 ± .8 (0.9)	-0.8 ± .5 (-1.4)	n/a	1.6 ± .4 (4.0)	5.2 ± 1.4 (4.6)	8	73
2	.8 ± .7 (-0.8)	-0.4 ± .7 (1.6)	3.0 ± .4 (4.3)	3.2 ± .5 (3.8)	4.5 ± .4 (4.1)	8	49
3	.2 ± .3 (-0.0)	-0.1 ± .2 (-0.0)	1.8 ± .2 (5.5)	5.7 ± .4 (6.3)	2.8 ± .2 (3.9)	6	136
4	-0.3 ± .8 (-0.2)	2.7 ± .9 (1.2)	4.5 ± 1.1 (4.8)	4.7 ± .6 (4.9)	4.2 ± .6 (5.6)	7	42
5	.3 ± .9 (0.1)	.5 ± 1.3 (-.5)	1.3 ± .5 (3.4)	4.4 ± .6 (3.3)	n/a	n/a	35
6	1.4 ± .4 (1.1)	-0.3 ± .5 (1.0)	2.8 ± .4 (3.1)	1.6 ± .4 (3.7)	n/a	7	63
7	.5 ± .3 (1.0)	-1.0 ± .5 (.3)	2.4 ± .3 (3.5)	n/a	1.8 ± 1 (3.6)	7	52

SNR is the mean signal to noise ratio for the study. The across subject average time-activity curves corresponding to these data are presented in Figure 6.

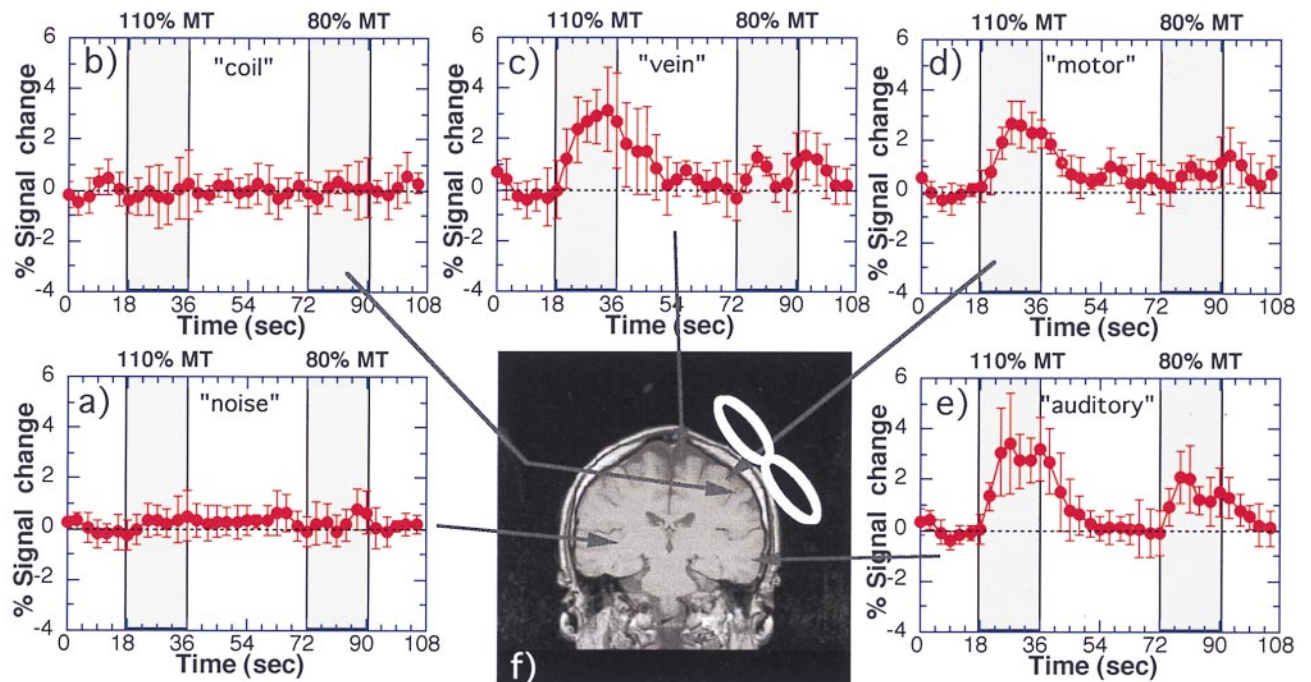


Figure 6. Cycle-averaged BOLD-signal versus time-within-cycle curves averaged over all seven subjects from pixel clusters in areas (see Table 1) selected for location. (A) Noise area remote from TMS coil and (B) coil area directly under TMS coil irrespective of activation, or *t*-map activation. (C) Medial (vein) area, (D) motor area, and (E) auditory area, all referenced to (F) a structural image from one subject to indicate approximate location.

mirror area on the contralateral side of the brain. Though it is not statistically significant in the EPI fMRI images, this susceptibility-induced signal loss is clearly seen in phantom studies, and may, by reducing the SNR, reduce the statistical significance of clusters in the area, dropping them below our acceptance cutoff. However, a search of the *t*-maps for low-significance clusters under the coil has not supported this explanation. Hence, the susceptibility effect, which reduces the SNR under the coil, may not totally explain the paucity of activated clusters observed directly under the coil. We are currently studying this problem by comparing TMS-induced blood flow in motor cortex under the TMS coil with simultaneous volitional activation of the opposite cortex.

In the time-activity curves taken from activated areas, both in the auditory cortex and areas presumed to be motor cortex, the signal changes were consistent with BOLD activation levels commonly seen elsewhere (3 to 4%). Noise levels in the individual curves from activated areas, as well as in those from areas remote from the TMS coil (noise) were approximately 1%; a bit high, but consistent with each other. In the area under the coil (coil), noise levels were somewhat higher, around 1.5%, so the reduced SNR seemed to be due mainly to the susceptibility-induced reduction in signal, and not, for example, some percussive effect from the TMS coil's loud "snap." In summary, though the

reduced activity in the immediate area of the coil may be due to the reduced SNR, the relative lack of low-significance activation in the region has led us to believe that a neuronal inhibitory effect of the TMS cannot be ruled out. Further work in our lab is underway to investigate this complex issue.

The exact neurobiologic origin of the BOLD signal is unclear in this study, as it is in all other BOLD activation studies. That is, we cannot make a statement about whether TMS is causing activity in neurons, or glia, or which neurons (local synapses or corticospinal cells). We can make no statement about which cells are driving this effect, other than that during the supra-motor threshold activation, we are at least also causing activity in the descending corticospinal cells controlling thumb movement. Current theories hold that increased neuronal activity of any kind (excitatory or inhibitory) produces a transient anaerobic effect. This sets off a cascade of chemical messengers, many of which are still unclear, that result in vasodilation and an increase in the ratio of oxygenated to deoxygenated hemoglobin. This relatively increased oxy/deoxy-hemoglobin ratio produces increases in signal intensity as measured by T2*-weighted MRI and is called the BOLD effect. It is thought that the brain overcompensates for the initial anaerobic activity, both in the amount of oxyhemoglobin sent, and in the amount of brain that receives the increased blood flow. The brain

“drowns the garden for the sake of one thirsty flower” (Malonek and Grinvald 1996).

With this study design alone one cannot be certain that the increase in BOLD response in the high intensity stimulation is due to corticospinal stimulation alone, as there is also the possibility of sensory feedback from the moving thumb to the motor cortex that might add to the differential signal. Future studies with more a complex design (e.g., including passive movement of the thumb as another “task”) are necessary to answer this point.

This study also suffers from a relatively primitive method of mounting the coil and determining the location without EMG confirmation. Other groups are experimenting with robotic placement of the TMS coil guided either by a probabilistic brain (Alan Evans, McGill, personal communication) or the actual person’s brain (Peter Fox, UTSW, personal communication). The initial work with these robotic guidance systems is being done with PET, with possible later extension into the more challenging high field MRI environment.

We also chose for this initial study a simple two-level change in dose. Later studies will use a more complex parametric design. Finally, we have not yet been able to totally eliminate the artifact produced by having the TMS coil in the MRI scanner. Our phantom studies provide some reassurance that the effects seen in this study are not artifactual. However, it seems very clear that depending on where the artifact is thrown, one would not be able to make statements about that region. Further work designing better coils with less artifact will help in this regard.

Finally, though our reason for choosing this as our first study was the hope that the auditory and somatosensory effects would be similar because the two administrations of TMS were only a little below (80%) and a little above (110%) motor threshold, the two intensity levels clearly show different levels of BOLD response in auditory cortex. This may mean that our comparison of the effects from the two different intensities is confounded by TMS-induced auditory and somatosensory response, and must be repeated with a more sophisticated design. Since any such interference will likely depend on the study, it will have to be addressed on a case by case basis.

Review of Other Imaging and TMS Studies

Although combining TMS with functional neuroimaging offers much promise, the literature as a whole to date has been difficult to integrate and synthesize. One of the major stumbling blocks is finding imaging techniques that temporally match the TMS stimulation. For safety reasons, at moderate intensities one can only stimulate at high frequencies for short periods (1 to 6 sec) before risking a seizure (Pascual-Leone et al 1993). Hence, before the

current study, the options have been to scan with low temporal resolution methods (PET) at low frequencies, or to scan at higher frequencies and have part of the functional image (tracer uptake) encompass periods of TMS rest. Additional problems concern the interaction of the TMS coil with the camera and resultant image, much as we describe in this current fMRI/TMS study.

The first published example of concurrent TMS and functional imaging was by George and colleagues in 1995 (George et al 1995), who imaged a patient undergoing TMS for treatment of depression. FDG PET scans (where the tracer can be injected away from the camera) were obtained at baseline prior to treatment, and then after several weeks. They then injected FDG while simultaneously and intermittently stimulating at high frequency (20 Hz) over the left prefrontal cortex and noted a global increase in brain glucose utilization. TMS at low frequency (1 Hz) over the prefrontal cortex has been found to both globally reduce brain activity compared to sham, and reduce activity in transynaptic regions (caudate, thalamus) (Kimbrell et al 1997).

O15 PET has a much shorter time frame (approximately 1 min), so it requires that the TMS machine be placed in the PET gantry. A study of TMS applied on the gantry outside of the scanner with a later picture found no changes (Hamano et al 1993). The first group to use TMS and O15 PET found that 10 Hz TMS applied over the frontal eye fields had dose-dependent increases in blood flow at the stimulation site (Paus et al 1997). Surprisingly, when the investigators used the identical setup but shifted the coil to motor cortex, they found a dose-dependent reduction in blood flow in motor cortex despite the fact that the thumb was moving (Paus et al 1998). Fox and colleagues found that TMS over the motor cortex at 1 Hz caused increases in blood flow (Fox et al 1997), although there is controversy about the area that was identified as being primary motor cortex.

Stallings and colleagues used perfusion SPECT with a tracer uptake of approximately 30 to 40 sec to image brain activity changes during left prefrontal TMS at high frequency (20 Hz) (Stallings et al 1997). In healthy adults, they found relative decreases at the coil site and in the anterior cingulate and orbitofrontal cortex. Recently Nahas and colleagues confirmed this relative decrease with SPECT in a depressed cohort as well (Nahas et al 1998). Rounding out the techniques that have been merged with TMS, Ilmoniemi and colleagues merged EEG with TMS and found regional increases in activity that shifted over time (Ilmoniemi et al 1997). EEG clearly has the best temporal window of all of the techniques (milliseconds), although the spatial resolution is poor.

A major problem with these TMS imaging studies is their small sample sizes. Thus, when results are inconsis-

tent (e.g., the two Paus PET studies showing dose-dependent increases in one study and decreases in another), it is unclear whether this is simply due to large individual variation in response and small sample sizes. Because fMRI allows one to make statements within individuals prior to pooling the data, one can explicitly examine this issue.

Conclusions

A review of the inconsistent imaging findings to date underscores the need for an imaging method with good spatial and temporal resolution where one can be exactly sure of the coil location. Combining TMS and MRI may be the answer. Thus we demonstrated that supra-motor threshold TMS over motor cortex elicits significantly more regional activity (BOLD effect) than sub-motor threshold. Further, the magnitude and temporal onset of TMS-induced blood flow changes is similar to that induced using other motor and cognitive activation tasks. This study also shows that combined TMS/fMRI is feasible and relatively safe, but that much work remains in refining the method and understanding its limitations and artifacts.

Compared to other imaging techniques, MRI is noninvasive and offers good spatial resolution (1 to 2 mm) and moderate time resolution (2 to 3 sec for changes in blood flow, perhaps better in the future with single event studies). Further, by using MRI phase maps, one can also image the exact magnetic field produced by TMS (Bohning et al 1997). In the near future, MRI may even be able to produce an image of the TMS-induced electrical field which current theories hold is the necessary precursor to the neurobiologic effects of TMS. Combining MRI and TMS offers great promise as a neuroscience tool, both to understand the brain effects of TMS and to test theories of brain organization, by stimulating brain circuits and monitoring simultaneous changes in brain activity and behavior.

Research collaborations with Picker International, Dantec (Medtronic). Partial equipment and salary support from the National Alliance for Research in Schizophrenia and Depression (NARSAD) (Young Investigator and Independent Investigator Awards, Dr. George) and the Ted and Vada Stanley Foundation (Drs. George, Bohning, Ms. McConnell and Roberts). Ms. Teneback was funded through NIAAA Center Grant # AA10761-03.

The authors also thank Drs. Jeremy Young, James Ballenger and George Arana for administrative support for this project.

References

- Bohning DE, Pecheny AP, Epstein CM, Vincent DJ, Dannels WR, George MS (1997): Mapping transcranial magnetic stimulation (TMS) fields in vivo with MRI. *Neuroreport* 8:2535–2538.
- Bohning DE, Shastri A, Nahas Z, et al (1998): Echoplanar BOLD fMRI of brain activation induced by concurrent transcranial magnetic stimulation (TMS). *Invest Radiol* 33(6):336–340.
- Figiel GS, Epstein C, McDonald WM, et al (1998): The use of rapid rate transcranial magnetic stimulation (rTMS) in refractory depressed patients. *J Neuropsychiatry Clin Neurosci* 10:20–25.
- Forman SD, Cohen JD, Fitzgerald M, Eddy WF, Mintun MA, Noll DC (1995): Improved assessment of significant activation in functional magnetic resonance imaging (fMRI): Use of a cluster-size threshold. *Magn Reson Med* 33:636–647.
- Fox P, Ingham R, George MS, et al (1997): Imaging human intra-cerebral connectivity by PET during TMS. *Neuroreport* 8:2787–2791.
- George MS, Wassermann EM (1994): Rapid-rate transcranial magnetic stimulation (rTMS) and ECT. *Convuls Ther* 10(4): 251–253.
- George MS, Wassermann EM, Post RM (1996): Transcranial magnetic stimulation: A neuropsychiatric tool for the 21st century. *J Neuropsychiatry Clin Neurosci* 8:373–382.
- George MS, Wassermann EM, Williams WA, et al (1995): Daily repetitive transcranial magnetic stimulation (rTMS) improves mood in depression. *Neuroreport* 6:1853–1856.
- George, M.S., Wassermann, E.M., Williams, W.E., Kimbrell, T.A., Little, J.T., Hallett, M., & Post, R.M. (1997). Mood Improvements Following Daily Left Prefrontal Repetitive Transcranial Magnetic Stimulation in Patients with Depression: A placebo-controlled crossover trial. *American Journal of Psychiatry*, 154, 1752–1756.
- George, M.S., Nahas, Z., Bohning, D.E., Shastri, A., Teneback, C.C., Roberts, D., Speer, A.M., Lorberbaum, J., Vincent, D.J., Owens, S.D., Kozel, A.F., Molloy, M. & Risch, S.C. (1999). Transcranial Magnetic Stimulation and Neuroimaging. In M.S. George & R.H. Belmaker (Eds.). *Transcranial Magnetic Stimulation in Neuropsychiatry* Washington, DC: American Psychiatric Press.
- Grafman J, Pascual-Leone A, Alway D, Nichelli P, Gomez-Tortosa E, Hallett M (1994): Induction of a recall deficit by rapid-rate transcranial magnetic stimulation. *Neuroreport* 5:1157–1160.
- Hamano T, Kaji R, Fukuyama H, Sadato N, Kimura J (1993): Lack of prolonged cerebral blood flow change after transcranial magnetic stimulation. *Electroencephalogr Clin Neurophysiol* 89:207–210.
- Ilmoniemi RJ, Virtanen J, Ruohonen J, et al (1997): Neuronal response to magnetic stimulation reveal cortical reactivity and connectivity. *Neuroreport* 8:3537–3540.
- Kimbrell TA, George MS, Danielson AL, et al (1997): Changes in cerebral metabolism during transcranial magnetic stimulation. *Biol Psychiatry* 41:108S–#374 (Abstract).
- Malonek D, Grinvald A (1996): Interactions between electrical activity and cortical microcirculation revealed by imaging spectroscopy: Implications for functional brain mapping. *Science* 272:551–554.

- Nahas Z, Stallings LE, Speer AM, et al (1998): Perfusion SPECT studies of rTMS on blood flow in health and depression. *Biol Psychiatry* 43:195-163.
- Pascual-Leone A, Houser CM, Reese K, et al (1993): Safety of rapid-rate transcranial magnetic stimulation in normal volunteers. *Electroencephalogr Clin Neurophysiol* 89:120-130.
- Pascual-Leone, A., Rubio, B., Pallardo, F., & Catala, M.D. (1996). Beneficial effect of rapid-rate transcranial magnetic stimulation of the left dorsolateral prefrontal cortex in drug-resistant depression. *The Lancet*, 348, 233-237.
- Paus T, Jech R, Thompson CJ, Comeau R, Peters T, Evans AC (1998): Dose-dependent reduction of cerebral blood flow during rapid-rate transcranial magnetic stimulation of the human sensorimotor cortex. *J Neurophysiol* 79: 1102-1107.
- Paus T, Jech R, Thompson CJ, Comeau R, Peters T, Evans AC (1997): Transcranial magnetic stimulation during positron emission tomography: A new method for studying connectivity of the human cerebral cortex. *J Neurosci* 17:3178-3184.
- Pridmore S, Filho JAF, Nahas Z, Liberatos C, George MS (1998): Motor threshold in transcranial magnetic stimulation: A comparison of a neurophysiological and a visualization of movement method. *ECT* 14:25-27.
- Rosvold H, Mirsky A, Saranson I, et al (1956): A continuous performance test of brain damage. *J Consul Clin Psychol* 20:343-350.
- Shastri A, Bohning DE, George MS (1998): Interleaving transcranial magnetic stimulation with steady state magnetic resonance imaging of the brain. *Neuroimage* 7:S686 (Abstract).
- Shastri A, George MS, Bohning DE (1999): Performance of a system for interleaving transcranial magnetic stimulation with steady state magnetic resonance imaging. *Electroencephalogr Clin Neuro*
- Stallings LE, Speer AM, Spicer KM, Cheng KT, George MS (1997): Combining SPECT and repetitive transcranial magnetic stimulation (rTMS)—Left prefrontal stimulation decreases relative perfusion locally in a dose dependent manner. *Neuroimage* 5:S521 (Abstract).
- Woods RP, Cherry SR, Mazziotta JC (1992): Rapid automated algorithm for aligning and reslicing PET images. *J Comput Assist Tomogr* 16:620-633.